

Management of mandibular compromised ridges: A case series.

Sruti Mukhopadhyay¹, Shreya Bandyopadhyay¹, Samiran Das²

¹PGT, Dept. of Prosthodontics and Crown & Bridge, Guru Nanak Institute of Dental Sciences and Research, Panihati, Kolkata.

²Professor, Dept. of Prosthodontics and Crown & Bridge, Guru Nanak Institute of Dental Sciences and Research, Panihati, Kolkata.

Abstract

Rehabilitation of compromised ridges is a challenging task for a clinician especially when the underlying denture bearing area is not conducive enough to perform its optimum function of retention, stability and support. This case series will give an insight on how to deal with compromised ridges by modifying few steps of our conventional impression making.

Key words – Compromised mandibular ridges, Flabby ridges, Knife-edge ridges, Neutral zone technique.

Address of correspondence: : Dr. Sruti Mukhopadhyay, 3 M.C Lahiri Street, Chatra, Serampore, Hooghly, WB- 712204.

Email address: - sruti1894@gmail.com **Phone no:** 9674656375. **DOI:** 10.5281/zenodo.6987159

Submitted: 22-June-2022 **Revised:** 11-Jul-2022 **Accepted:** 27-Jul-2022 **Published:** 15-Aug-2022

Bibliographic details: Journal of Orofacial Rehabilitation Vol. 2(2), Aug 2022, pp. 71-76.

Introduction

The clinical performance of a removal complete denture depends on accurate and precise impression making of the supporting and limiting areas of the underlying residual ridge. Difficulty arises when the residual ridges become compromised as a consequence of an inevitable biologic phenomena called residual ridge resorption (RRR). Resorption of residual ridge is a complex biological phenomenon characterized by decreased amount and form of residual ridge after teeth are extracted. In 1971, Resorption of residual ridges has been described by *Atwood* as a “Major Oral Disease Entity”.^[1] The major change which takes place as a consequence of RRR is effective decrease in the dimensions of the denture bearing area.

Commonly encountered compromised residual ridge condition may include:

- Patient with atrophic ridges
- Flabby ridges
- Knife-edges ridges

This series of case reports will give an insight about the various treatment procedures of three patients with compromised ridges using modified fabrication techniques.

CASE REPORT 1

Atrophic ridges

Neutral zone technique

A 78 years old female patient came to the Dept. of Prosthodontics and Crown & Bridge, Guru Nanak Institute of Dental Science and research, Kolkata with a primary complaint of difficulty in speech and mastication due to previously fabricated ill-fitting upper and lower complete dentures. On examination, the mandibular ridge was found to be severely atrophied. (Figure. 1). The treatment plan was to opt for neutral zone technique for the atrophied lower ridge. Irreversible hydrocolloid impression material was used for the diagnostic impressions, primary casts were poured on which custom trays were fabricated and using all-green technique^[2] (Figure. 2), a secondary impression was made for the mandibular arch. After subsequent border moulding, light body addition silicone

was used for the final impression and master casts were poured and a record base was fabricated using self-polymerizing resin. The denture bases had three 22-gauge orthodontic wire loops on which type 1, low-fusing border moulding material was placed and this record base was transferred to the patient's mouth and various functional movements (sipping a glass of water, pronouncing vowels like a,e,i,o,u) was performed by the patient (Figure. 3 and 4).^[3] The green stick impression material was eventually moulded according to the patient's neutral zone and the denture base was mounted in an articulator maintaining the vertical dimension which was previously recorded. A plaster index was made, using which monoplane teeth were arranged in both the arches in the recorded neutral zone (Figure. 5).

CASE REPORT 2

Flabby Ridges

Window technique

A 79 years old male patient came to our department with a primary concern of loosening of previously fabricated complete denture. On examination, the patient was found to be completely edentulous in both the arches. A flabby mandibular ridge extending from edentulous right canine region to left canine region was seen (Figure. 6). The treatment plan was to fabricate maxillary and mandibular dentures with modification for the flabby ridge area. The maxillary complete denture was fabricated using the conventional fabrication procedure. For the mandibular denture, an admixed impression^[4] (Figure. 7) was made followed by pouring of a plaster cast on which custom trays were made using self-cure polymerizing resin. Following muscle trimming procedure, and final impression by zinc oxide eugenol, a window was created in the flabby tissue region which extended from lower left canine

edentulous area to the lower right canine region. A low viscosity light cure impression material was placed over the cut window and the flabby tissue was recorded under static condition (Figure. 8).^[5]

CASE REPORT 3

Knife-edged ridge

Differential pressure technique

A 47 years old female patient reported to our department with a chief complaint of pain on mastication for the last 3 months due to ill-fitting mandibular denture. On examination, it was seen that the patient was completely edentulous in both the arches. The mandibular ridge was knife edged throughout the region extending from left second molar to right second molar (Figure. 9). The treatment option was to go for the fabrication of the mandibular denture using differential pressure technique.^[6] The maxillary denture was fabricated in a conventional way. For the mandibular ridge, the final impression was made using medium body impression material (Figure. 10). Using a scalpel blade, the medium body impression was removed in the region of previously mentioned knife edged ridge. Multiple escape holes were made in the same region and a light body impression material was loaded on the tray and the knife edge ridge was recorded (Figure. 11).

Discussion

The major problem faced by compromised residual ridges are inadequate retention, stability and support. Many surgical procedures can be advocated in order to increase the retention and stability, but as compromised ridges are mainly seen in older patients, these patients are unlikely to undergo any kind of surgical intervention. As per the dictum of MM Devan^[7], perpetual

preservation of what is remaining and using modified impression and fabrication techniques, maximum stability and comfort can be provided to these patients. Several modified impression techniques for compromised ridges have been advocated in the literature like admixed, all-green, window-technique, differential pressure technique^[2]. The primary objective of these techniques was to attain maximum coverage of the remaining denture bearing area with a relief provided on the flabby or knife-edge region.

The 'neutral zone' is the effective space wherein the buccally directed forces of the tongue muscles are counterpoised by the inward directed forces originating by labial and the buccal musculature.^[8] The main ideology behind placing the denture in neutral zone is to determine a space where the denture will attain maximum stability without being displaced under the forces exerted by the tongue and buccal or labial musculature.

Fibrous or flabby ridges are mobile soft tissues that are present on the superficial aspect of the alveolar ridge. These lesser resilient tissues cause complete displacement of dentures under masticatory loading. The main objective behind treatment of flabby ridges is muco-compressive impression for normal tissues and muco-static impression for flabby tissues.^[9]

Knife edge ridges are commonly seen in mandible and comes under stage 4 of Atwood Classification of resorbed ridges. Rapid bone resorption is seen at the lingual and the buccal areas leaving behind a sharp bony ridge edentulous ridge. The main objective of impression making is to formulate a technique that will distribute the masticatory load onto the other areas of the residual ridge and will provide relief over the sharp crestal region.^[10]


Conclusion

Modifying few impression making procedures can be of a great benefit for the patients with compromised ridges. This will not only provide physiological solace to them but will also aid psychologically and in terms of overall satisfaction.

References

1. Atwood DA. Post extraction changes in the adult mandible as illustrated by microradiographs of midsagittal sections and serial cephalometric roentgenograms. *Journal of Prosthetic Dentistry* 1963; 13:810–824.
2. Freese AS. Impressions for unfavorable mandibular ridges. *The Journal of Prosthetic Dentistry*. 1956 May 1;6(3):302-4.
3. Prithviraj DR, Singh V, Kumar S, Shruti DP. Conservative prosthodontic procedures to improve mandibular denture stability in an atrophic mandibular ridge. *The Journal of Indian Prosthodontic Society*. 2008; 8:178.
4. McCord JF, Tyson KW. A conservative prosthodontic option for the treatment of edentulous patients with atrophic (flat) mandibular ridges. *British Dental Journal*. 1997; 182:469–472 .
5. Osborne J. Two impression methods for mobile fibrous ridges. *British Dental Journal*. 1964;117(6):392-4.
6. Hyde TP. Case report: differential pressure impressions for complete dentures. *The European Journal of Prosthodontics and Restorative Dentistry*. 2003 Mar 1;11(1):5-8.
7. DeVan MM. Basic principles in impression making. *The Journal of*

- Prosthetic Dentistry. 1952 Jan 1;2(1):26-35.
8. TNCotAo P. The glossary of prosthodontic terms. The Journal of Prosthetic Dentistry. 2005; 94:10-92.
9. Manoj SS, Chitre V, Aras M. Management of compromised ridges: a case report. The Journal of Indian Prosthodontic Society. 2011 Jun;11(2):125-9.
10. Jennings DE. Treatment of the mandibular compromised ridge: a literature review. The Journal of Prosthetic Dentistry. 1989 May 1;61(5):575-9



FIGURES

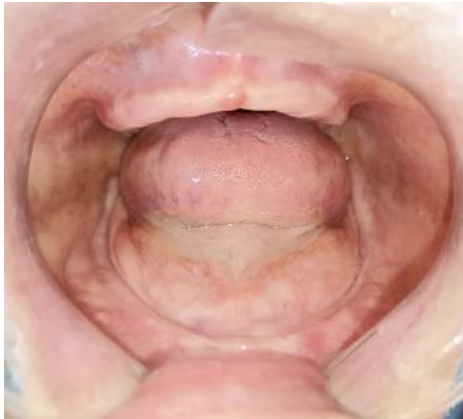

Figure 1



Figure 2



Figure 3




Figure 4

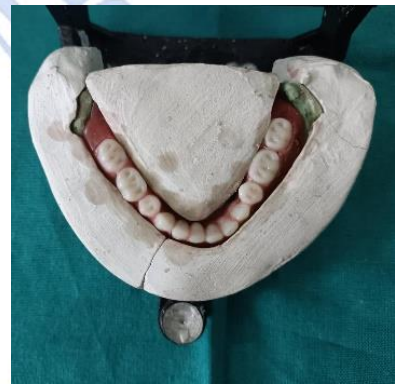

Figure 5

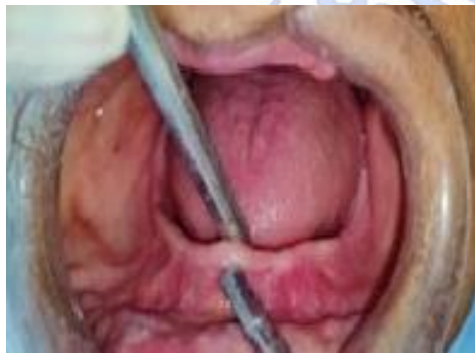

Figure 6



Figure 7

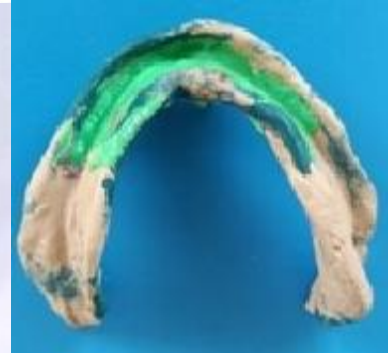

Figure 8

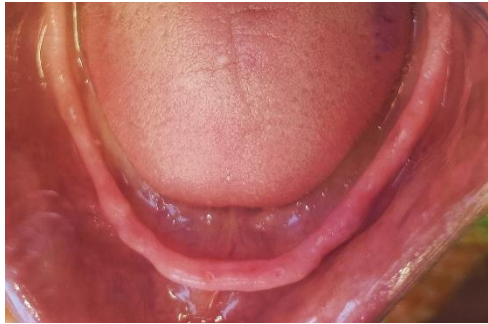

Figure 9

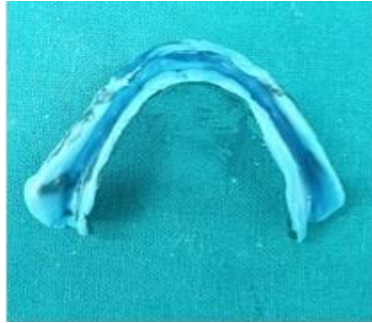

Figure 10



Figure 11

